Autologous Chondrocyte Implantation "Sandwich" Technique Compared With Autologous Bone Grafting for Deep Osteochondral Lesions in the Knee

Tom Minas,*† MD, MS, Takahiro Ogura,†‡ MD, Jeff Headrick,§ MD, and Tim Bryant,† BSN, RN
Investigation performed at the Cartilage Repair Center, Brigham and Women's Hospital, Harvard Medical School, Boston, Massachusetts, USA

Background: Treating symptomatic osteochondral defects is challenging, especially in young adults with deep (>8-10 mm) empty defects after osteochondritis dissecans (OCD) or collapsed condyles secondary to avascular necrosis (AVN). For this population, osteoarthritis (OA) is inevitable if articular congruence is not restored.

Purpose: To describe the autologous chondrocyte implantation (ACI) "sandwich" technique with autologous bone grafting (ABG) and compare it with ABG alone for restoration of the osteochondral unit. The midterm to long-term outcomes in patients after the treatment for OCD and AVN will be reported and compared.

Study Design: Cohort study; Level of evidence, 3.

Methods: The outcomes for a consecutive cohort of 24 patients who underwent combined ABG with the ACI sandwich technique between 2001 and 2013 (ACI sandwich group) was compared with a historical control group of 17 consecutive patients who underwent ABG alone between 1995 and 2002 (ABG group) by a single surgeon for symptomatic deep (>8 mm) osteochondral lesions. Patients who were followed up with a minimum of 2 years were included in this study. The modified Cincinnati Knee Rating System, the Western Ontario and McMaster Universities Osteoarthritis Index, a visual analog scale (VAS), the Short Form–36, and a patient satisfaction survey were used to evaluate clinical outcomes. Survival analysis was performed using the Kaplan-Meier method, with no clinical improvement, graft failure, or conversion to prosthetic arthroplasty as the endpoint (failure). Kellgren-Lawrence (K-L) grading to assess OA progression was also performed.

Results: In the ABG group, 13 of 17 patients (76%) were available with a mean follow-up of 15.7 years postoperatively (range, 5-21 years). In the ACI sandwich group, all 24 patients were available with a mean follow-up of 7.8 years postoperatively (range, 2-15 years). No significant differences were observed between the groups in terms of age, sex, side of the operated knee, body mass index, lesion type, lesion size, lesion depth, lesion location, or the need for realignment osteotomy. Eight patients (62%) were considered failures in the ABG group, while 3 patients (13%) were considered failures in the ACI sandwich group. The survival rate was significantly better in the ACI sandwich group than the ABG group (87% vs 54% at 5 years, respectively; $P = .0025$). All functional scores in patients with retained grafts significantly improved in the ACI sandwich group, whereas only the VAS score showed significant improvement in the ABG group. The patient satisfaction survey showed a very high satisfaction rate in the ACI sandwich group, with over 90% of patients reporting their knees as good or excellent and being satisfied with the procedure. In the ACI sandwich group, K-L grading demonstrated no significant OA progression from preoperatively to a mean 5.1 years postoperatively.

Conclusion: Our study showed that the ACI sandwich technique provided excellent and superior survival rates compared to ABG alone and significant improvements over midterm to long-term follow-up. This unique treatment offers native joint preservation for conditions that naturally will progress to OA and eventually require prosthetic arthroplasty.

Keywords: autologous chondrocyte implantation; osteochondral lesion; autologous bone grafting; sandwich technique, articular; cartilage; repair

The treatment of a deep osteochondral defect in the knee is one of the most difficult conditions for orthopaedic surgeons to manage. Fragment removal of an osteochondritis dissecans (OCD) lesion produces an incongruous joint surface, which uniformly leads to osteoarthritis (OA).[29,40] Once a femoral condyle with avascular necrosis (AVN)

The American Journal of Sports Medicine
1–11
DOI: 10.1177/0363546517738000

collapses (Ficat stage III[12]), OA ensues. Although a variety of surgical procedures have been developed for their management, the optimal surgical technique is still controversial.[10,15,24] Techniques that include fragment removal,[1,2,33,47] debridement,[25,33] drilling,[26] abrasion chondroplasty,[21] and microfracture[41] have been shown to result in fibrocartilage,[34] which has inferior mechanical properties to hyaline cartilage. These techniques may have merit in the short term for shallow lesions <5 to 8 mm deep without sclerotic subchondral bone or subchondral cystic changes. Autologous chondrocyte implantation (ACI) has demonstrated excellent midterm results for these lesions.[36] However, once defects become deeper (>8-15 mm) and have associated subchondral cystic and sclerotic bone changes, the osteochondral unit requires bone and cartilage restoration. Techniques for deep osteochondral defects include osteochondal autograft transplantation,[19] fresh matched osteochondral allograft transplantation (OCA),[14,16,17] autologous bone grafting (ABG) in isolation,[22,44] and the recently described ACI sandwich technique.[3,4,31,46]

When confronted with deep (>8-10 mm), large empty, or collapsed osteochondral defects arising from OCD or idiopathic AVN (not secondary AVN due to chemotherapeutic agents, steroids, alcohol, sickle cell crises, etc), the single treating surgeon for both treatment groups sought to restore the osseous and cartilaginous surface as a functional osteochondral unit. Background factors including alignment and joint stability were identified and reconstructed at the same time. The indications and principles for reconstruction have not changed over the 2 decades of the study. In the early 1990s after personal communication with Lanny Johnson, his described technique of ABG[44] was utilized, followed by rehabilitation including protected weightbearing and continuous passive motion (CPM). The goal was to restore the osseous portion of the distal femur and perform fibrocartilage surface repair. If the technique failed clinically, as defined by persistent pain and swelling after 6 to 12 months postoperatively, magnetic resonance imaging (MRI) and arthroscopic surgery would be performed to confirm failure by insufficient or poor-quality repair tissue after ABG. A biopsy for cultured chondrocytes would then be taken for second-stage ACI (Carticel; Vericel) to restore the articular surface.

Jones and Peterson[23] developed and presented cases of the ACI "sandwich" technique in the early 2000s (personal communication) as a single open operative procedure of ABG and ACI. The cultured chondrocytes were separated from the graft and marrow space by "sandwiching" the cells between 2 periosteal membranes on the surface as single-stage autologous reconstruction of the osteochondral unit. ABG in isolation was used from 1995 to 2002 and then abandoned in favor of the ACI sandwich technique from 2001 to the present. The technique has remained the same except that the periosteal membrane was replaced with a type I/III collagen bilayer membrane in 2007 (Bio-Gide; Geistlich Pharma). The ACI sandwich technique includes 2 types: ACI "full sandwich," with ACI cartilage repair covering the "full" area of bone grafted, and ACI "segmental sandwich," with the bone graft just a "segment" of the overall defect area treated by ACI (which will not be reviewed in this study to maintain a homogeneous population of comparators).

The purpose of this study was to evaluate clinical outcomes after the ACI full sandwich technique and compare it to ABG in isolation over the midterm to long-term follow-up in this difficult patient population of large, deep osteochondral defects of the knee.

METHODS

Patient Selection

The study was approved by an institutional review board, and informed consent was obtained from all patients. A single surgeon (T.M.) performed all the procedures over the 2 decades of the study. Data were prospectively collected. Between March 1995 and April 2002, 17 consecutive patients underwent ABG alone for symptomatic deep osteochondral lesions secondary to OCD or idiopathic AVN (Ficat stage III). Between April 2001 and June 2013, 24 consecutive patients underwent combined ABG with the ACI full sandwich technique. ACI cartilage repair covered the "full" area of bone grafted and consisted of defects similar in cause and size to the ABG-treated osteochondral defects. Patients who were followed up with a minimum of 2 years were included in this study. Indications for surgery included osteochondral defects larger than 2 cm^2 in size and deeper than 8 to 10 mm, with symptoms matching the defect location. The bone defect was measured using a small paper ruler after radical debridement to healthy bone, measuring the length, width, and depth of the osteochondral defect. Surgery was only indicated in patients who were resistant to nonoperative therapies, including physical therapy and steroid injections. Patients were evaluated with a physical examination, radiography, computed tomography, MRI, and arthroscopic surgery before treatment was considered. Contraindications to surgery included inflammatory joint disease; unresolved or recent septic arthritis; metabolic or crystal disorders; and AVN secondary to steroids, alcohol, chemotherapeutic agents, and sickle cell crises, among others. Articular comorbidities, such as malalignment and patellar maltracking, were corrected at the time of surgery. Tibiofemoral malaligment >2° to 3° was corrected via osteotomy of the tibia or femur, with correction of the

*Address correspondence to Tom Minas, MD, MS, Cartilage Repair Center, Brigham and Women's Hospital, Harvard Medical School, 850 Boylston Street, Suite 112, Chestnut Hill, MA 02467, USA (email: tminas@outlook.com).

†Cartilage Repair Center, Brigham and Women's Hospital, Harvard Medical School, Boston, Massachusetts, USA.

‡Sports Medicine Center, Funabashi Orthopaedic Hospital, Funabashi, Japan.

§Center for Orthopedic Surgery, Lubbock, Texas, USA.

One or more of the authors has declared the following potential conflict of interest or source of funding: T.M. is a consultant for Vericel. This study was supported by a grant from the Cartilage Research Foundation.

mechanical axis to neutral or 0°. Malalignment was determined by bilateral stance long alignment radiographs to include the hip-knee-ankle. Before January 2003, high tibial osteotomy (HTO) with closing-wedge osteotomy was performed, which changed to an opening wedge after February 2003. Patellofemoral maltracking was addressed with anteromedialization tibial tubercle osteotomy to centralize patellar tracking[13,32] and proximal soft tissue balancing (lateral release, vastus medialis obliquus advancement) as necessary to centralize the extensor mechanism.

Surgical Technique

ABG and the ACI sandwich technique were performed as previously described.[22,31,46] For ABG, after arthrotomy, the chondral defect was removed, and the sclerotic or necrotic bone was debrided back to healthy-appearing bone and cartilage tissue with a high-speed bur under constant irrigation (Figure 1). The base of the bony cavity was multiply drilled to enhance the blood supply and healing. The bony cavity was prepared to slightly undermine the subchondral bone surface around the articular margins, with the depth of the cavity wider than the opening, much like a dental amalgam, so that the cancellous bone chips, when impacted with a bone tamp, would maintain inherent stability. Autologous cancellous bone chips were harvested locally with a core reamer and backfilled with cancellous allograft chips or used from closing-wedge tibial osteotomy or the iliac crest when necessary. The autologous cancellous bone was morselized and impacted up to the level of the native subchondral bone plate. If the bone graft appeared to be unstable, an absorbable 5.0 or 6.0 Vicryl suture (Ethicon) was woven across the articular surface (n = 5) (Figure 1). The knee was brought into full extension and the tourniquet let down to allow the bone marrow–derived cells to form a "superclot" at the surface of the graft, hopefully producing repair tissue on the surface under the influence of CPM and protected weightbearing postoperatively.

For the ACI sandwich technique, a periosteal patch (n = 11) was used before May 2007, whereas a type I/III collagen bilayer membrane (n = 13), derived from porcine peritoneum and skin (Bio-Gide), was used after May 2007. In conjunction with ABG, when a periosteal patch was used, the first periosteal patch was glued with Tisseel fibrin glue (Baxter International) and a few tacking sutures used circumferentially over the bone graft with 6-0 resorbable suture with the cambium layer facing out. The periosteum was then covered with a neural patty, the leg brought into full extension, and the tourniquet let down. The knee was gently flexed up and the neural patty gently removed, ensuring that the base of the defect was dry with no marrow-derived blood present. Then, a second periosteal patch was microsutured on the articular surface at intervals of 3 to 5 mm circumferentially, with the cambium layer facing the defect. The margins were then sealed watertight with Tisseel fibrin glue, and the autologous cultured chondrocytes were then injected between the 2 membranes, where they were "sandwiched" between the cambium layers of the periosteum or collagen membranes. The ACI full sandwich technique is described in Figure 2.

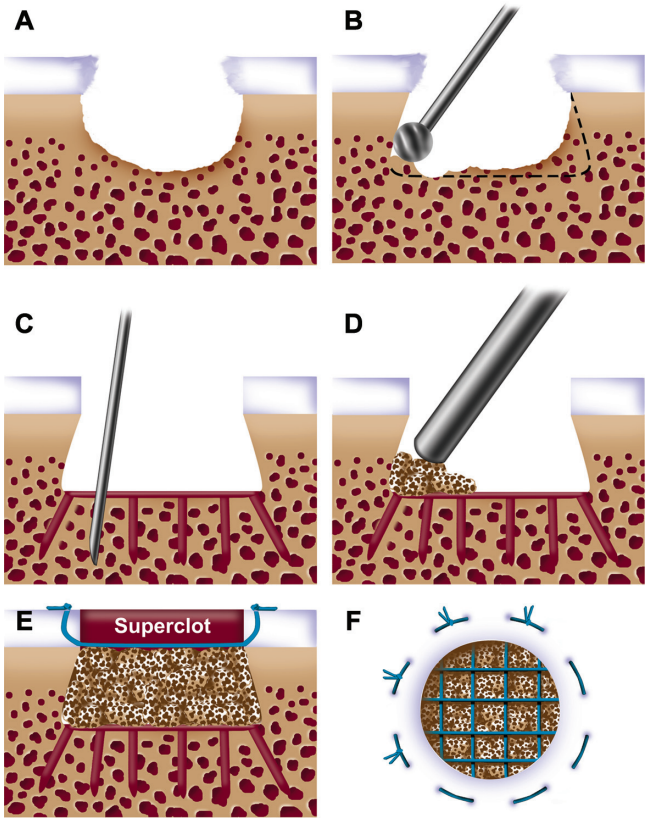

Figure 1. Technique for autologous bone grafting. (A) An osteochondral cavitary defect >8 to 10 mm deep is shown. (B) After removing the abnormal bone and widening the base, the surface opening is narrower like a dental amalgam to hold the graft to be delivered. (C) Drilling is performed to enhance the blood supply. (D) Cancellous autologous bone chips are then packed into the base of the defect up to the surface. (E) Microsutures are added if the graft is unstable when placed through several cycles of range of motion, and the tourniquet is let down with the knee in extension to obtain a marrow-derived ''superclot,'' which can then differentiate into repair tissue during careful rehabilitation. (F) Top view after microsuturing as a ''fishnet'' pattern to maintain the graft in place if unstable. (Reprinted with permission from Minas.[31])

Postoperative Course

Postoperatively, patients were instructed to use a CPM machine for 6 to 8 hours daily for 6 weeks. Patients were encouraged to start riding a stationary bicycle with no resistance as early as 3 weeks, and to increase resistance after 6 weeks as long as there was no joint crepitus or pain. Patients were flat-foot touch weightbearing for 6 weeks, with a gradual progression to full weightbearing between 7 and 12 weeks. Patients were allowed to return to most activities of daily living after 3 months and to noncontact inline sporting activities without cutting movements after 4 to 6 months, such as outdoor bicycling, treadmill walking, elliptical training, swimming, rollerblading, and hiking.

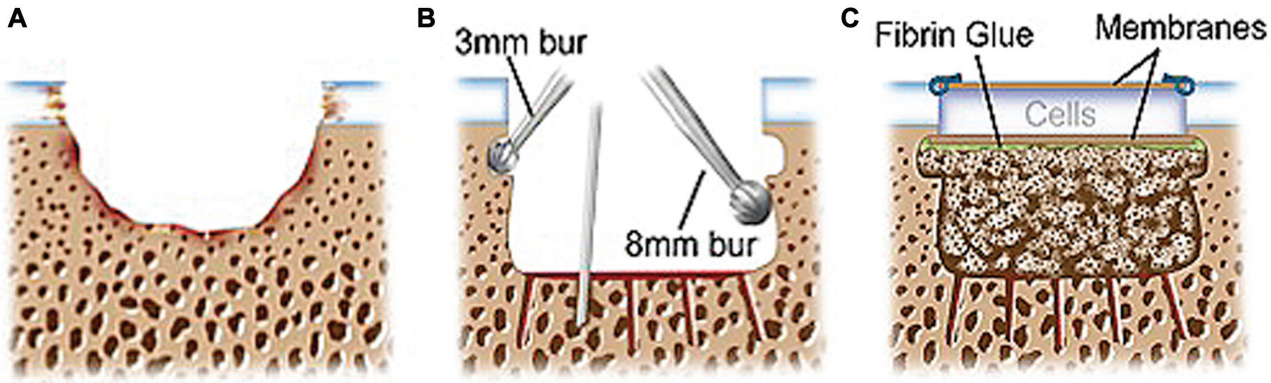

Figure 2. Technique for autologous chondrocyte implantation full sandwich. (A) The osteochondral defect shows that the size of the bone defect and overlying chondral defect are similar. (B) A high-speed bur, usually 8 mm in diameter, removes all subchondral sclerotic bone back to healthy-appearing spongy bone. The base is multiply drilled with a Kirschner wire to enhance the blood supply to the autologous bone grafting site. Then, a 3 mm–diameter bur undermines the subchondral bone to secure the membrane when it is glued to the graft with overlying gentle pressure, covered by a neural patty, as the tourniquet is let down when the knee is brought into full extension. The neural patty is removed, and the defect is separated and dry from the underlying marrow space and bone graft. (C) The second membrane is then sutured to the surface and sealed with fibrin glue. Cultured chondrocytes are then injected or ''sandwiched'' between the 2 membranes.

After 12 to 14 months, inline jogging was permitted if there was no swelling or pain evident. Pivoting activities were permitted from 14 to 18 months postoperatively. The postoperative recovery protocol was individually adjusted according to the defect location, concurrent procedures, degree of graft maturation, and previous activity level.

Failure Definition

Treatment failure for ABG alone was defined as no clinical improvement and evidence on MRI and arthroscopic surgery of insufficient or poor-quality repair tissue, at which time a biopsy specimen was taken for articular resurfacing by ACI. Failure for the ACI sandwich group was defined as recurrent symptoms of pain and catching leading to MRI or arthroscopic surgery demonstrating graft failure that required repeat biological osteochondral debridement, repair, or conversion to prosthetic arthroplasty.

Survival Analysis and Clinical Outcome Evaluation

Survival analysis was performed using the Kaplan-Meier method. Outcome measures included the modified Cincinnati Knee Rating System (Figure 3),[8,30] Western Ontario and McMaster Universities Osteoarthritis Index (WOMAC),[6] visual analog scale (VAS), and Short Form–36 (SF-36). Patients also self-reported knee function and satisfaction. Scores were collected preoperatively and at the latest follow-up during consultations or via a mailed questionnaire.

Radiographic Evaluation

Anteroposterior and lateral standing radiographs of the knee were assessed in accordance with the Kellgren-Lawrence (K-L) grade[27] to determine if there was any OA progression from baseline.

Statistical Analysis

Differences in patient demographics and characteristics of osteochondral defects were compared using an unpaired t test or the Mann-Whitney U test for continuous data based on the distribution of data determined by the Shapiro-Wilk test. For categorical data, the Fisher exact test or Pearson chi-square test was used as appropriate. Kaplan-Meier curves were used for survival analyses, followed by log-rank analysis. The Wilcoxon signed-rank test was used to compare differences in functional scores (obtained from the modified Cincinnati, VAS, WOMAC, and SF-36) between the 2 time points (preoperatively and at last follow-up). Mann-Whitney U tests were used to compare the improvement in scores between the groups. The level of significance was set a priori at $P < .05$. All statistical analyses were performed with Stata (version 13; StataCorp).

RESULTS

Patient Cohort

In the ABG group, 13 of 17 patients were available for follow-up (76%) at a mean of 15.7 years postoperatively (range, 5-21 years; 2 patients were lost to follow-up, and 2 were deceased). In the ACI full sandwich group, 24 patients were available for follow-up (100%) at a mean of 7.8 years postoperatively (range, 2-15 years). No significant differences were observed between the groups in terms of age, sex, side of the operated knee, body mass index, lesion type, lesion size, lesion depth, and lesion location at the time of the index surgery (Tables 1 and 2). In addition to the osteochondral lesions in the ACI full sandwich group, 6 patients had a total of 6 chondral defects (4 lesions in the patella, 1 in the trochlea, and 1 in the lateral tibial

☐ 1 ☐ 2 ☐ 3 ☐ 4 ☐ 5 ☐ 6 ☐ 7 ☐ 8 ☐ 9 ☐ 10	
POOR FAIR GOOD VERY GOOD EXCELLENT	
Poor (1-2)	I have significant limitations that affect activities of daily living.
Fair (3-4)	I have moderate limitations that affect activities of daily living. No sports possible.
Good (5-6)	I have some limitations with sports but I can participate; I compensate.
Very Good (7-8)	I have only a few limitations with sports.
Excellent (9-10)	I am able to do whatever I wish (any sport) with no problem.

Figure 3. Modified Cincinnati Knee Rating System: overall score.

TABLE 1
Patient Characteristics[a]

	ABG (n = 13)	ACI Full Sandwich (n = 24)	*P* Value
Age at surgery, mean (range), y	33 (15-54)	30 (14-51)	.3843
Sex, male/female, n	8/5	13/11	.739
Knee, right/left, n	6/7	15/9	.489
Body mass index, mean (range), kg/m^2	26.3 (19.2-35.9)	26.3 (19.7-37.1)	.9908
Lesion type, n (%)			.639
Osteochondritis dissecans	8 (61.5)	16 (66.7)	
Avascular necrosis	3 (23.1)	4 (16.7)	
Cyst	0 (0.0)	2 (8.3)	
Failed microfracture	2 (15.4)	2 (8.3)	

[a]ABG, autologous bone grafting; ACI, autologous chondrocyte implantation.

TABLE 2
Defect Size and Location[a]

	ABG (n = 13)	ACI Full Sandwich (n = 24)	*P* Value
Area, mean ± SD (range), cm^2	7.1 ± 2.7 (3-12)	6.9 ± 3.1 (2-12.5)	.6631
Depth, mean ± SD (range), cm	1.2 ± 0.4 (0.7-1.8)	1.1 ± 0.3 (0.8-1.5)	.6256
Defect location, n (%)			.593
Medial femoral condyle	10 (77)	17 (71)	
Lateral femoral condyle	3 (23)	3 (13)	
Trochlea	0 (0)	2 (8)	
Patella	0 (0)	1 (4)	
Medial tibial plateau	0 (0)	1 (4)	

[a]ABG, autologous bone grafting; ACI, autologous chondrocyte implantation.

plateau) with a mean size of 3.4 ± 1.5 cm^2 (range, 2.0-5.3 cm^2), which were treated as a secondary defect with ACI during the index surgery. Before the index surgery, 7 of the 13 patients in the ABG group had undergone a mean of 1.3 surgeries (range, 1-2), and 18 of the 24 patients in the ACI full sandwich group had undergone a mean of 1.8 surgeries (range, 1-3). Seven patients underwent concomitant osteotomy in the ABG group and 17 patients in the ACI full sandwich group (P = .287) (Table 3). During ACI full sandwich surgery, a periosteal patch was used in 11 patients and a collagen membrane in 13 patients.

Survival Analysis

In the ABG group, all patients had 5 and 10 year follow-up. In the ACI full sandwich group, 22 and 12 patients had 5 and 10 year follow-up, respectively. In the ABG group, the survival rate was 54% (95% CI, 25%-76%) and 45% (95% CI, 18%-70%) at 5 and 10 years postoperatively, respectively. In the ACI full sandwich group, the survival rate was 87% (95% CI, 66%-96%) at 5 and 10 years postoperatively. There was a significant difference between these 2 groups (P = .0025) (Figure 4).

TABLE 3
Concomitant Osteotomy[a]

	ABG (n = 13)	ACI Full Sandwich (n = 24)	*P* Value
HTO	6 (46) (closing wedge)	8 (33) (closing/open wedge: 4/4)	.287
TTO	0 (0)	5 (21)	
HTO + TTO	1 (8) (closing wedge)	3 (13) (closing/open wedge: 1/2)	
DFO + TTO	0 (0)	1 (4)	
Total	7 (54)	17 (71)	
No concomitant osteotomy	6 (46)	7 (29)	

[a]Data are presented as n (%). ABG, autologous bone grafting; ACI, autologous chondrocyte implantation; DFO, distal femoral osteotomy; HTO, high tibial osteotomy; TTO, tibial tubercle osteotomy.

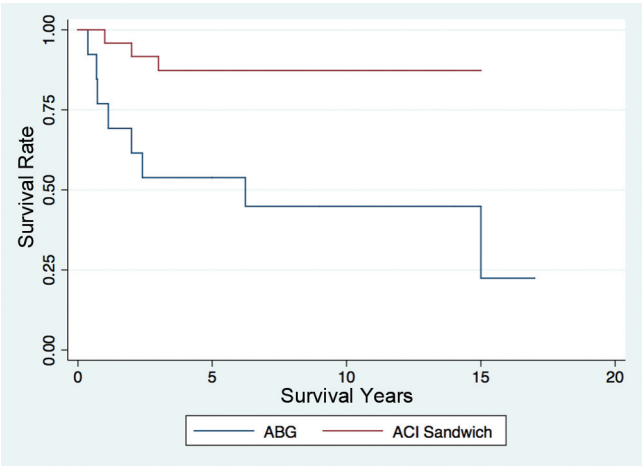

Figure 4. Kaplan-Meier survival curve. Overall survival rate in the autologous bone grafting (ABG) group (n = 13) and autologous chondrocyte implantation (ACI) full sandwich group (n = 24). The endpoint was defined as failure of the graft.

In the ABG group without concomitant osteotomy (n = 6), the survival rate was 17% (95% CI, 1%-52%) at 5 years and 0% at 10 years postoperatively. In the ACI full sandwich group without concomitant osteotomy (n = 7), 7 and 5 patients had 5 and 10 year follow-up, respectively. The survival rate was 71% (95% CI, 26%-92%) at 5, 10, and 15 years postoperatively. There was a significant difference between these 2 groups (P = .0025) (Figure 5).

In the ABG group with concomitant osteotomy (n = 7), the survival rate was 86% (95% CI, 33%-98%) at 5 and 10 years postoperatively but deteriorated to 43% (95% CI, 1.1%-85%) at 15 years. In the ACI full sandwich group with concomitant osteotomy (n = 17), 15 and 7 patients had 5 and 10 year follow-up, respectively. The survival rate was 94% (95% CI, 63%-99%) at 5, 10, and 15 years postoperatively. Although

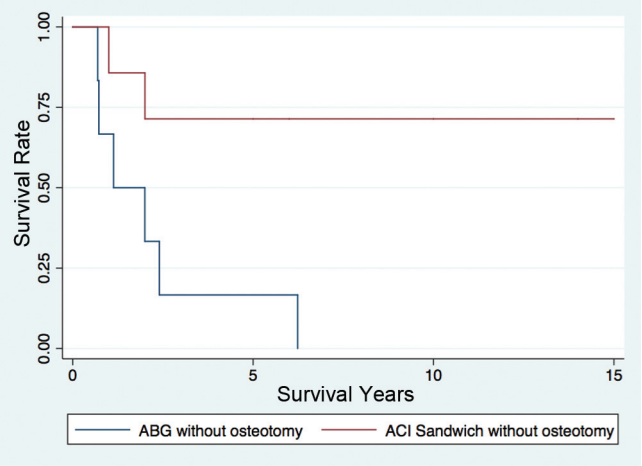

Figure 5. Kaplan-Meier survival curve. Survival rate without concomitant osteotomy in the autologous bone grafting (ABG) group (n = 6) and autologous chondrocyte implantation (ACI) full sandwich group (n = 7). The endpoint was defined as failure of the graft.

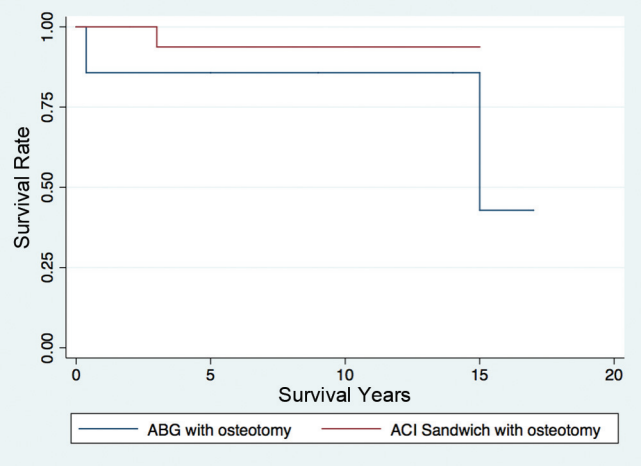

Figure 6. Kaplan-Meier survival curve. Survival rate with concomitant osteotomy in the autologous bone grafting (ABG) group (n = 7) and autologous chondrocyte implantation (ACI) sandwich group (n = 17). The endpoint was defined as failure of the graft.

the trend was that the ACI sandwich technique did better at 15 years, it did not reach statistical significance between these 2 groups (P = .2476) (Figure 6).

Functional Outcomes

There were 5 patients with intact grafts in the ABG group at final follow-up. In these patients, only the VAS score showed significant improvement. All other scores except the SF-36 improved but failed to reach statistical significance. In the ACI full sandwich group, all functional scores showed significant clinical and statistical improvements (Table 4).

TABLE 4
Preoperative and Postoperative Functional Scores in Patients With Retained Grafts[a]

	ABG (n = 5)			ACI Full Sandwich (n = 24)		
	Preoperative	Postoperative	*P* Value	Preoperative	Postoperative	*P* Value
Modified Cincinnati	2.6 ± 0.9	4.6 ± 2.3	.0556	3.0 ± 0.8	5.7 ± 2.0	.0001
VAS	6.4 ± 1.1	3.4 ± 0.9	.0412	6.7 ± 1.4	2.9 ± 1.6	<.0001
WOMAC total	59.0 ± 34.7	25.2 ± 21.8	.0796	48.7 ± 17.5	18.6 ± 11.1	<.0001
WOMAC pain	12.6 ± 1.5	7.4 ± 3.8	.0796	10.3 ± 3.9	3.6 ± 2.6	<.0001
WOMAC stiffness	4.6 ± 2.1	2.2 ± 1.9	.0545	4.2 ± 2.3	2.0 ± 1.2	.0012
WOMAC function	41.8 ± 5.1	15.6 ± 16.5	.0782	34.2 ± 13.6	13.0 ± 8.0	.0001
SF-36 PCS	38.2 ± 6.2	36.9 ± 3.4	.8927	37.7 ± 9.5	47.3 ± 10.5	.0004
SF-36 MCS	41.5 ± 6.9	41.1 ± 4.4	.5002	48.8 ± 6.4	54.2 ± 4.5	.0036

[a]Data are presented as mean ± SD at final follow-up. ABG, autologous bone grafting; ACI, autologous chondrocyte implantation; MCS, mental component summary; PCS, physical component summary; SF-36, Short Form–36; VAS, visual analog scale; WOMAC, Western Ontario and McMaster Universities Osteoarthritis Index.

TABLE 5
Satisfaction With Surgery at Final Follow-up[a]

Question	ABG (n = 5/13)	ACI Full Sandwich (n = 24/24)
What is your overall satisfaction level with your joint surgery?		
Satisfied	3 (60)	23 (96)
Neutral	1 (20)	1 (4)
Dissatisfied	1 (20)	0 (0)
If you could go back in time and make the decision again, would you choose to have your joint surgery?		
Yes	3 (60)	24 (100)
Uncertain	2 (40)	0 (0)
No	0 (0)	0 (0)
How would you rate the results of your joint surgery?		
Good/excellent	4 (80)	22 (92)
Fair	1 (20)	2 (8)
Poor	0 (0)	0 (0)

[a]Data are presented as n (%). ABG, autologous bone grafting; ACI, autologous chondrocyte implantation.

TABLE 6
Preoperative and Postoperative K-L Grading in ABG Group[a]

Patient	Outcome	Preoperative/ Postoperative K-L Grade	Radiographic Follow-up, y	Revision Surgery
1	Success	1/2	16.3	None
2	Failure	2/3	12.6	TKA at 15 y
3	Failure	1/1	4.5	ACI at 2.0 y
4	Failure	1/1	5.2	ACI at 1.1 y
5	Failure	1/2	10.5	ACI at 6.2 y

[a]ABG, autologous bone grafting; ACI, autologous chondrocyte implantation; K-L, Kellgren-Lawrence; TKA, total knee arthroplasty.

Patient Satisfaction

Satisfaction in patients with retained grafts after ABG (60%) was acceptable, whereas it was excellent in patients after the ACI sandwich technique at 96% (Table 5). Notably, all patients who underwent the ACI full sandwich technique answered that they would choose to undergo their surgery if they could go back.

Radiographic Evaluation

In the ABG group, 5 of 13 patients were available to review. The other films were not available because many films were destroyed after the conversion to digital radiography. These 5 patients included 1 successfully treated patient with ABG, 1 patient who converted to total knee arthroplasty (TKA), and 3 patients who required subsequent ACI surgery. Details are shown in Table 6.

In the ACI full sandwich group, 16 of 24 patients (including 3 patients with treatment failure) were available for a radiographic evaluation at a mean of 5.1 years postoperatively (with a minimum of 2 years postoperatively; range, 2-11.4 years). There was no significant difference in the level of OA based on K-L grading before and after surgery (P = .0833). The OA grade did not increase in 13 patients (81.3%). An increase of 1 point based on K-L grading was observed in 3 patients (18.7%) (Table 7).

Subsequent Surgical Procedures

In the ABG group, 3 patients (23%) required a mean of 1 subsequent surgical procedure at a mean of 2.7 years (range, 0.9-6.2 years) postoperatively, including arthroscopic chondroplasty, free body removal, and hardware removal. All 3 patients proceeded to treatment failure.

In the ACI full sandwich group, 16 patients (67%) required a mean of 1.8 subsequent surgical procedures (range, 1-4) at a mean of 2.1 years (range, 1 month to 11.4 years) postoperatively, including ACI graft hypertrophy in 9, lysis of adhesion in 7, removal of painful hardware in 4, debridement of the membrane flap in 2, trochleoplasty in 1, removal of retained sutures in 1, removal of a loose body in 1, arthroscopic meniscectomy in 1, and compartment syndrome in 1. The majority of

TABLE 7
Preoperative and Postoperative
K-L Grading in ACI Full Sandwich Group[a]

	ACI Full Sandwich (n = 16)
K-L grade	
Preoperative, mean ± SD	1.1 ± 0.3
Postoperative, mean ± SD	1.3 ± 0.4
P value	.0833
Time to evaluation, mean ± SD (range), y	5.1 ± 2.8 (2-11.4)
Increase in K-L grade, n (%)	
+0	13 (81.3)
+1	3 (18.7)

[a]Minimum 2 years postoperatively. ACI, autologous chondrocyte implantation; K-L, Kellgren-Lawrence.

subsequent surgical procedures were performed arthroscopically and successfully managed. Among them, 2 patients who had periosteal hypertrophy proceeded to treatment failure.

Failures

In the ABG group, 8 patients were considered to have failures. One patient underwent tibial tubercle osteotomy and removal of an allogenic bone graft to the lateral femoral condyle at 2.4 years postoperatively. However, this patient failed again and underwent ABG again at 3.4 years after the index surgery. Then, this patient eventually underwent ACI and revision tibial tubercle osteotomy at 8.3 years after the index surgery. Seven patients, including the first patient, underwent ACI at a mean of 1.9 years postoperatively because of persistent pain. Of these 7 patients, all but 1 (patient 5) were successfully managed with ACI and have continued to do well. One patient (patient 5) underwent revision ACI, followed by arthroplasty at 6.2 years postoperatively. One patient (patient 2) was converted to TKA at 15 years postoperatively.

In the ACI full sandwich group, 3 patients were considered to have failures at a mean of 1.9 years postoperatively because of partial graft failure. They underwent arthroscopic chondroplasty, did well, and required no further treatment (Table 8).

DISCUSSION

In this review of prospectively collected data, we compared the outcomes for patients who underwent combined ABG with ACI (ACI sandwich technique) and those for patients who underwent ABG alone for symptomatic deep osteochondral lesions. Our study showed that the ACI sandwich technique provided excellent and superior survival rates compared with ABG alone, with significant and clinically meaningful improvements in pain and function over midterm to long-term follow-up. Additionally, the ACI sandwich technique provided a very high patient satisfaction rate (96% for ACI sandwich vs 60% for ABG). Moreover, this technique could prevent the progression of OA based on K-L grading and allowed all patients to avoid arthroplasty during this study period.

Recently, Johnson et al[22] have reported long-term outcomes after ABG for the treatment of OCD and osteonecrosis. Their cohort of patients with OCD included 2 different groups: one with ABG plus repair of the cartilage fragment and the other one with ABG without the cartilage fragment. The former group underwent ABG with fixation of the fragment, and the latter underwent ABG alone. They reported clinical improvement in both the groups; however, no validated score system was reported. Additionally, it should be noted that half of the patients with osteonecrosis who had undergone ABG were converted to arthroplasty within an average of 6 years (range, 1-12 years). This relatively high failure rate was consistent with our results that showed that 2 of 3 patients with AVN failed after ABG alone (1 patient with ACI at 5 months; the other patient with TKA at 15 years). Moreover, when considering that they treated an older population (mean age, 47 years) than our cohort (mean age, 30 years in the ACI sandwich group), ABG alone appears not to be a suitable option for young, active patients who were counseled to have lessened expectations for symptoms and activities after ABG by Johnson et al.[22]

Our results of the ACI sandwich technique were comparable with those of previous studies that reported good clinical outcomes after ACI combined with ABG for the treatment of osteochondral defects but our study had more patients and much longer follow-ups. These previous studies included sandwich matrix-induced ACI with ABG as a modification of the ACI sandwich technique,[4,45] single-layer matrix-induced ACI with ABG,[35,42] and ACI with a monocortical autologous bone cylinder.[7] Peterson et al[36] reported good outcomes after first-generation ACI, including the ACI sandwich technique for deep osteochondal defects. However, specific results focusing on the patients who underwent the ACI sandwich technique were not reported. There were a few case reports regarding outcomes after the ACI sandwich technique.[3,46] To our knowledge, our study reporting outcomes after ACI with ABG was the longest follow-up study with the largest sample size and with a historical control of patients treated with ABG alone.

Recently, Sadr et al[39] evaluated the clinical outcomes of 135 patients (149 knees) who underwent OCA for the treatment of OCD with a mean of 6.3 years' follow-up. They reported an excellent survival rate of 95% at 5 years and 93% at 10 years, which were comparable with our results in the patients who underwent the ACI full sandwich technique (87% at 5 and 10 years). When compared with the study by Sadr et al,[39] however, our cohort consisted of older patients, additional chondral lesions treated with ACI, and a greater number of previous surgeries before the index surgery, which lead us to believe that we treated more patients with more complex issues. Nevertheless, the ACI sandwich technique provided an excellent and comparable survival rate. Previous studies reported that the results of fresh OCA were unfavorable in patients older than 30 years and with a previous number of surgeries

TABLE 8
Outcomes in Patients Who Failed[a]

Patient	Group	Age and Sex	Cause	Cartilage Lesion	Area, cm^2/Depth, cm	Revision Surgery
1	ABG	18 M	OCD	LFC	8.0/1.0	Bone allograft at 2.4 y, ABG at 3.4 y, ACI at 8.3 y
2	ABG	54 M	AVN	MFC	7.0/1.0	TKA at 15 y
3	ABG	15 F	OCD	LFC	4.0/2.0	ACI at 2.0 y
4	ABG	23 F	OCD	MFC	10.0/1.5	ACI at 8 mo
5	ABG	33 F	OCD	MFC	10.5/1.0	ACI at 1.1 y, revision ACI at 2.8 y, UKA at 6.2 y
6	ABG	50 M	AVN	MFC	8.8/1.0	ACI at 5 mo
7	ABG	17 M	OCD	LFC	12.0/0.7	ACI at 8 mo
8	ABG	29 M	OCD	MFC	3.0/0.8	ACI at 6.2 y
9	ACI	14 F	OCD	LFC	7.8/1.5	ASC at 2 y
10	ACI	14 M	OCD	LFC	12.5/1.5	ASC at 1 y
11	ACI	28 M	OCD	MFC	11.3/2.0	ASC at 2.7 y

[a]ABG, autologous bone grafting; ACI, autologous chondrocyte implantation; ASC, arthroscopic chondroplasty; AVN, avascular necrosis; F, female; LFC, lateral femoral condyle; M, male; MFC, medial femoral condyle; OCD, osteochondritis dissecans; TKA, total knee arthroplasty; UKA, unicompartmental knee arthroplasty.

greater than 2.[9,28] No prior study has had such excellent survivorship for OCA as Sadr et al[39] likely because of the tertiary nature, high volume, and surgical skill at that institution. It is difficult to make a direct comparison because of the variations in patient and lesion demographics. Only a randomized controlled study will determine the optimal treatment for deep osteochondral defects. Controversy still exists regarding the outcome after OCA in patients with osteonecrosis. Bayne et al[5] showed worse outcomes in patients with steroid-induced osteonecrosis, whereas Gortz et al[16] reported reasonable outcomes.

Although 67% of the patients who underwent the ACI full sandwich technique required a mean of 1.8 subsequent surgical procedures, the very high patient satisfaction rate is encouraging. This observation can be probably explained by the fact that the majority of the subsequent surgical procedures were performed arthroscopically and that the patients were able to recover quickly after the procedures.

Our radiographic evaluation demonstrated the possible prevention of OA progression in the ACI full sandwich group. Given that previous studies have shown that empty OCD defects lead to degenerative changes in the joint,[29,40,43] the ACI full sandwich technique delayed or prevented the development of OA progression over a mean of 5.1 years (range, 2-11.4 years) by restoring congruence of the osteochondral unit. Further evaluations with a longer follow-up will be needed to confirm this observation.

Regarding the functional scores at the latest follow-up, significant improvements in all functional scores were observed in the ACI sandwich group, whereas only the VAS score significantly improved in the ABG group. The smaller size of the ABG group may have limited its power to demonstrate statistically significant differences between preoperative and postoperative scores. The difference in the follow-up period made a direct comparison impossible between these 2 groups. However, patients who underwent ABG did not function well even at the earlier follow-up. A previous study showed that patients after ABG exhibited persistent low-grade pain and swelling,[22] which was consistent with our results after ABG. Thus, the ACI sandwich technique that provided significantly and clinically meaningful improvements can be an option to allow a more active lifestyle.

Subanalysis for the survival rate showed that there was a significant difference between ABG and the ACI sandwich technique when performed without concomitant osteotomy, whereas there was a trend toward a better outcome with the ACI sandwich technique that did not reach a significant difference between the groups when performed with concomitant osteotomy. Our results showed that ABG with osteotomy provided a good survival rate within 10 years (survival rate, 86%) but deteriorated at 15 years (survival rate, 43%), which were consistent with several studies that showed that isolated HTO resulted in a good survival rate within 10 years but deteriorated after 15 years.[18,20,37,38] On the other hand, the survival rate for the ACI sandwich technique with concomitant osteotomy was sustained to 15 years (survival rate, 94%), which we believe is because of more durable regenerative tissue than ABG. A small sample size might have hindered the detection of a statistical difference between ABG with osteotomy and the ACI sandwich technique with osteotomy. Thus, a further investigation with a larger sample size and longer follow-up will be warranted to find any benefits of cartilage procedures when performed with osteotomy.

Changing the surgical technique from closing-wedge osteotomy to open-wedge osteotomy should be noted. The principles utilized consistently over the 2 decades of this study have remained the same for the same indications and stages of disease: a midline skin incision, rigid internal fixation, long alignment axial correction to the middle of the intercondylar eminences (midline), and identical postoperative rehabilitation. However, according to a recent systematic review,[11] 3.5% of patients undergoing open-wedge HTO (20/573 patients) progressed to TKA at a mean of 4.8 years (range, 1.2-14 years), whereas 7.1% of patients undergoing closing-wedge HTO (17/238 patients) progressed to TKA at a mean of 9.6 years (range, 2-15 years). Thus, closing-wedge HTO appears to be twice as likely to fail than open-wedge HTO. Nevertheless, in our

study, all 5 patients undergoing closing-wedge HTO in the ACI sandwich group did not fail during the study period, although a longer follow-up is needed. We believe that the difference in the surgical technique (closing- vs open-wedge osteotomy) did not influence the survival rate in our presented results likely because of the adherence of our consistent principles for both types of osteotomy.

The strength of this study was that this was a single-surgeon series with the same indications and rehabilitation for both treatment groups. However, there were several limitations. First, we did not have an empty defect group as a control. However, given that the patients were resistant to nonoperative treatment with disabling symptoms before surgery, it was unacceptable to not offer them a surgical treatment. Second, this study set the ABG group as a historical control and was not a randomized study. However, the baseline patient and defect demographics were comparable. Third, some patients were lost to follow-up in the ABG group (2 were deceased, and 2 were lost to follow-up), although we had a relatively high and acceptable follow-up rate (76%). Fourth, 7 patients who underwent ABG alone were considered as failures when they were salvaged by ACI, as their symptoms remained unacceptable by ABG alone. Although this decision was made based on the clinical symptoms, MRI, and arthroscopic surgery, it possibly introduced an observer bias. Fifth, the length of follow-up was different substantially in the 2 groups, although we tried to mitigate it by performing Kaplan-Meier analysis. Finally, we were unable to review all the radiographs because of the conversion to digital films over the 20 years of this study. However, as other studies failed to report a radiographic follow-up, we believe that even a limited number of radiographs available could offer important information about OA prevention.

In conclusion, our study showed that the ACI full sandwich technique provided excellent and superior survival rates (87% at 5 and 10 years) compared with ABG alone (54% and 45% at 5 and 10 years, respectively) and significant improvements in pain and function over the midterm to long-term follow-up. Moreover, a very high patient satisfaction rate of 96% was predictable. This unique treatment offers native joint preservation for conditions that naturally will progress to OA and require prosthetic arthroplasty by restoring congruence and the osteochondral unit.

ACKNOWLEDGMENT

The authors gratefully thank Victoria Allen, BS, and Nicole Adam, BS, for their assistance in collecting and managing the long-term data for this study.

REFERENCES

1. Aglietti P, Ciardullo A, Giron F, Ponteggia F. Results of arthroscopic excision of the fragment in the treatment of osteochondritis dissecans of the knee. *Arthroscopy*. 2001;17(7):741-746.
2. Anderson AF, Pagnani MJ. Osteochondritis dissecans of the femoral condyles: long-term results of excision of the fragment. *Am J Sports Med*. 1997;25(6):830-834.
3. Aurich M, Anders J, Trommer T, Liesaus E, Wagner A, Venbrocks R. Autologous chondrocyte transplantation by the sandwich technique. *Unfallchirurg*. 2007;110(2):176-179.
4. Bartlett W, Gooding CR, Carrington RW, Skinner JA, Briggs TW, Bentley G. Autologous chondrocyte implantation at the knee using a bilayer collagen membrane with bone graft: a preliminary report. *J Bone Joint Surg Br*. 2005;87(3):330-332.
5. Bayne O, Langer F, Pritzker KP, Houpt J, Gross AE. Osteochondral allografts in the treatment of osteonecrosis of the knee. *Orthop Clin North Am*. 1985;16(4):727-740.
6. Bellamy N, Buchanan WW, Goldsmith CH, Campbell J, Stitt LW. Validation study of WOMAC: a health status instrument for measuring clinically important patient relevant outcomes to antirheumatic drug therapy in patients with osteoarthritis of the hip or knee. *J Rheumatol*. 1988;15(12):1833-1840.
7. Bhattacharjee A, McCarthy HS, Tins B, et al. Autologous bone plug supplemented with autologous chondrocyte implantation in osteochondral defects of the knee. *Am J Sports Med*. 2016;44(5):1249-1259.
8. Browne JE, Anderson AF, Arciero R, et al. Clinical outcome of autologous chondrocyte implantation at 5 years in US subjects. *Clin Orthop Relat Res*. 2005;436:237-245.
9. Chahal J, Gross AE, Gross C, et al. Outcomes of osteochondral allograft transplantation in the knee. *Arthroscopy*. 2013;29(3):575-588.
10. Chambers HG, Shea KG, Carey JL. AAOS Clinical Practice Guideline: diagnosis and treatment of osteochondritis dissecans. *J Am Acad Orthop Surg*. 2011;19(5):307-309.
11. Ekhtiari S, Haldane CE, de Sa D, Simunovic N, Musahl V, Ayeni OR. Return to work and sport following high tibial osteotomy: a systematic review. *J Bone Joint Surg Am*. 2016;98(18):1568-1577.
12. Ficat R, Arlet J. Necrosis of the femoral head. In: *Ischemia and Necrosis of Bone*. Baltimore: Lippincott Williams & Wilkins; 1980:171-182.
13. Fulkerson JP. Anteromedialization of the tibial tuberosity for patellofemoral malalignment. *Clin Orthop Relat Res*. 1983;177:176-181.
14. Garrett J. Fresh osteochondral allografts for treatment of articular defects in osteochondritis dissecans of the lateral femoral condyle in adults. *Clin Orthop*. 1994;303:33-37.
15. Gomoll AH, Madry H, Knutsen G, et al. The subchondral bone in articular cartilage repair: current problems in the surgical management. *Knee Surg Sports Traumatol Arthrosc*. 2010;18(4):434-447.
16. Gortz S, De Young AJ, Bugbee WD. Fresh osteochondral allografting for steroid-associated osteonecrosis of the femoral condyles. *Clin Orthop Relat Res*. 2010;468(5):1269-1278.
17. Gross AE, Shasha N, Aubin P. Long-term followup of the use of fresh osteochondral allografts for posttraumatic knee defects. *Clin Orthop Relat Res*. 2005;435:79-87.
18. Gstottner M, Pedross F, Liebensteiner M, Bach C. Long-term outcome after high tibial osteotomy. *Arch Orthop Trauma Surg*. 2008;128(1):111-115.
19. Hangody L, Fules P. Autologous osteochondral mosaicplasty for the treatment of full-thickness defects of weight-bearing joints: ten years of experimental and clinical experience. *J Bone Joint Surg Am*. 2003;85(suppl 2):25-32.
20. Hui C, Salmon LJ, Kok A, et al. Long-term survival of high tibial osteotomy for medial compartment osteoarthritis of the knee. *Am J Sports Med*. 2011;39(1):64-70.
21. Johnson L. Arthroscopic abrasion arthroplasty. In: McGinty J. ed. *Operative Arthroscopy*. New York: Raven Press; 1991:341-360.
22. Johnson LL, Delano M, Spector M, Pittsley A, Gottschalk A. The long-term clinical outcomes following autogenous bone grafting for large-volume defects of the knee: 12- to 21-year follow-up. *Cartilage*. 2014;5(2):86-96.
23. Jones D, Peterson L. Autologous chondrocyte implantation. *Instr Course Lect*. 2007;56:429-445.
24. Jones MH, Williams AM. Osteochondritis dissecans of the knee: a practical guide for surgeons. *Bone Joint J*. 2016;98(6):723-729.

25. Jurgensen I, Bachmann G, Schleicher I, Haas H. Arthroscopic versus conservative treatment of osteochondritis dissecans of the knee: value of magnetic resonance imaging in therapy planning and follow-up. *Arthroscopy*. 2002;18(4):378-386.
26. Kawasaki K, Uchio Y, Adachi N, Iwasa J, Ochi M. Drilling from the intercondylar area for treatment of osteochondritis dissecans of the knee joint. *Knee*. 2003;10(3):257-263.
27. Kellgren JH, Lawrence JS. Radiological assessment of rheumatoid arthritis. *Ann Rheum Dis*. 1957;16(4):485-493.
28. Levy YD, Gortz S, Pulido PA, McCauley JC, Bugbee WD. Do fresh osteochondral allografts successfully treat femoral condyle lesions? *Clin Orthop Relat Res*. 2013;471(1):231-237.
29. Linden B. Osteochondritis dissecans of the femoral condyles: a long-term follow-up study. *J Bone Joint Surg Am*. 1977;59(6):769-776.
30. Micheli LJ, Browne JE, Erggelet C, et al. Autologous chondrocyte implantation of the knee: multicenter experience and minimum 3-year follow-up. *Clin J Sport Med*. 2001;11(4):223-228.
31. Minas T. *A Primer in Cartilage Repair and Joint Preservation of the Knee: Expert Consult*. Philadelphia: Elsevier Health Sciences; 2011.
32. Minas T, Bryant T. The role of autologous chondrocyte implantation in the patellofemoral joint. *Clin Orthop Relat Res*. 2005;436:30-39.
33. Murray JR, Chitnavis J, Dixon P, et al. Osteochondritis dissecans of the knee: long-term clinical outcome following arthroscopic debridement. *Knee*. 2007;14(2):94-98.
34. Nehrer S, Spector M, Minas T. Histologic analysis of tissue after failed cartilage repair procedures. *Clin Orthop Relat Res*. 1999;365:149-162.
35. Ochs BG, Muller-Horvat C, Albrecht D, et al. Remodeling of articular cartilage and subchondral bone after bone grafting and matrix-associated autologous chondrocyte implantation for osteochondritis dissecans of the knee. *Am J Sports Med*. 2011;39(4):764-773.
36. Peterson L, Minas T, Brittberg M, Lindahl A. Treatment of osteochondritis dissecans of the knee with autologous chondrocyte transplantation: results at two to ten years. *J Bone Joint Surg Am*. 2003; 85(suppl 2):17-24.
37. Polat G, Balci HI, Cakmak MF, Demirel M, Sen C, Asik M. Long-term results and comparison of the three different high tibial osteotomy and fixation techniques in medial compartment arthrosis. *J Orthop Surg Res*. 2017;12(1):44.
38. Sabzevari S, Ebrahimpour A, Roudi MK, Kachooei AR. High tibial osteotomy: a systematic review and current concept. *Arch Bone Joint Surg*. 2016;4(3):204-212.
39. Sadr KN, Pulido PA, McCauley JC, Bugbee WD. Osteochondral allograft transplantation in patients with osteochondritis dissecans of the knee. *Am J Sports Med*. 2016;44(11):2870-2875.
40. Sanders TL, Pareek A, Obey MR, et al. High rate of osteoarthritis after osteochondritis dissecans fragment excision compared with surgical restoration at a mean 16-year follow-up. *Am J Sports Med*. 2017; 45(8):1799-1805.
41. Steadman J, Rodkey W, Singleton S, Briggs K. Microfracture technique for full-thickness chondral defects: technique and clinical results. *Oper Tech Orthop*. 1997;7(4):300-304.
42. Steinhagen J, Bruns J, Deuretzbacher G, Ruether W, Fuerst M, Niggemeyer O. Treatment of osteochondritis dissecans of the femoral condyle with autologous bone grafts and matrix-supported autologous chondrocytes. *Int Orthop*. 2010;34(6):819-825.
43. Twyman RS, Desai K, Aichroth PM. Osteochondritis dissecans of the knee: a long-term study. *J Bone Joint Surg Br*. 1991;73(3):461-464.
44. van Dyk GE, Dejardin LM, Flo G, Johnson LL. Cancellous bone grafting of large osteochondral defects: an experimental study in dogs. *Arthroscopy*. 1998;14(3):311-320.
45. Vijayan S, Bartlett W, Bentley G, et al. Autologous chondrocyte implantation for osteochondral lesions in the knee using a bilayer collagen membrane and bone graft: a two- to eight-year follow-up study. *J Bone Joint Surg Br*. 2012;94(4):488-492.
46. von Keudell A, Gomoll AH, Bryant T, Minas T. Spontaneous osteonecrosis of the knee treated with autologous chondrocyte implantation, autologous bone-grafting, and osteotomy: a report of two cases with follow-up of seven and nine years. *J Bone Joint Surg Am*. 2011;93(24):e149.
47. Wright RW, McLean M, Matava MJ, Shively RA. Osteochondritis dissecans of the knee: long-term results of excision of the fragment. *Clin Orthop Relat Res*. 2004;424:239-243.